

International Journal of Research in AYUSH and Pharmaceutical Sciences

Case Study

A CASE OF HAEMORRHAGIC OVARIAN CYST CURED WITH HOMOEOPATHIC SIMILIMUM

Aman Deep

Assistant Professor, Department of Community Medicine, Dr.MPK Homoeopathic Medical college and Research Center, Jaipur, India.

Keywords: Ovarian cyst, Homoeopathy, Lachesis

ABSTRACT

Haemorrhage in an ovarian cyst is very common. These cyst are known as haemorrhagic ovarian cysts (HOCs). Most of the cyst disappears spontaneously, but certain cyst requires surgical intervention. HOCs are formed because of occurrence of bleeding into a follicular or corpus luteum cyst. Allopathic system of medicine Prescribes various hormonal pills for its management which may have adverse drug reactions. Homoeopathic medicines are very helpful to manage such conditions. This article is about a case of 27 years old female who was suffering from haemorrhagic cyst. Homoeopathic medicine was given on the basis of totality of symptoms and patient cured within three months of treatment. Patient's consent has been taken for the publication of this case report.

INTRODUCTION

When internal hemorrhage occurs into functional cysts of the ovary it is called hemorrhagic ovarian cyst.^[1] When a graffian follicle ruptures to release an oocyte, it is transformed into corpus luteum. The corpus luteum is lined by a layer of granulose cells which rapidly becomes vascularized, some of these thin walled vessels may rupture, which causes bleeding into corpus luteum, resulting in formation of a hemorrhagic cyst of the ovary. Pain is the presenting symptoms of the patient which may be very severe, other minor symptom include menstrual irregularities. Large cyst greater than 5centimeter may rupture and may cause acute abdomen. Diagnosis of hemorrhagic cyst is made chiefly on the basis of clinical symptoms and ultrasonography. ^[1]

Homoeopathy is an alternative system of medicine, founded by Dr. Samuel Hahnemann (1755-1843), based on the therapeutic law "Similia Similibus Curenter" means" let likes be treated by likes'. The successful application of law of similar depends entirely on the concept of individualization and susceptible constitution ^[2] which is pillar of homoeopathic practice. Stuart close defines health as:"Health is that balanced condition of living organism in which the integral, harmonius

performance of the vital function tends to the preservation of the organism and the normal development of individual". ^[3] Miasma are the fundamental cause of every disease, so in order to cure a patient we must cure his constitutional dyscrasia. ^[4]

CASE REPORT

Presenting complaints

Location- Left ovarian fossa

Sensation- cutting pain

Modalities-

Aggravation- motion, touch, pressure

Amelioration- rest

Concomitant- white coated tongue

History of Presented complaints

Age 27 years old married female presented with complaints of severe pain in abdomen on left ovarian fossa since morning. Patient was suffering from similar type of pain since 1 year. Initially it was treated with analgesics at home. But pain reoccurred again and again near each menstrual period. Sometime pain also occurs during inter-menstrual period. On ultrasonogarpical examination there was presence of single hemorrhagic cyst of size 35 mm in left ovary.

Past history

H/o Jaundice at the age of 21 years
H/ of treatment of previous illness: Treated with allopathic medicines

Family history

Father- Hypertension
Mother- Diabetes Mellitus

Personal and social history

Addiction: None
Occupation: House-wife
Surrounding at home: Good
Habit: Not specific
Number of children: 1
Diet: Vegetarian

Physical Generals

Desire (foods and drinks): Sweets++
Aversion (foods and drinks): Not specific
Thirst: Thirsty
Thermal reaction: Hot
Appetite: Normal
Sleep: normal
Dreams: snakes+++v
Perspiration: profuse
Parts: back and Axilla
Stain/Odor: Yellow stain, offensive
Urine: (Nature, Color, frequency)-Regular D₄
Stool: Regular D₂

Menstrual symptoms

Menarche: 13 years
Duration of cycle: 5 days
Nature of flow (colors, quantity, quality, smell, stain etc): Profuse, bright red
Pain: No pain during menses

General Modalities

Aggravation: (Weather, time, circumstances etc)- at night
Amelioration: (Weather, time, circumstances etc)- not specific

Mental Generals

Patient married four year back. She has a male boy. Interpersonal relationship with husband was good. There was no history of domestic stress. She has having fear of snakes. Even she can't see snake in the television. She can't wear tight clothing around her neck. Patient is sensitive to pain. She has fear about her death and she things she is soon going to die.

Intellect- good
Memory- Sharp

Physical examination**General Physical Examination**

Build: Normal built
Nutrition: Good
Pallor: Absent
Jaundice: Absent
Cyanosis: Absent
Pigmentation: Absent
Clubbing: Absent
Oedema: Absent
Pulse: 78/ minute
Temperature: 98.6 F
Respiration Rate: 16 /minute
Blood pressure- 128/84mm/hg

Systemic examination

Per Abdomen
Inspection- No abnormality detected
Palpation- Tenderness over left ovarian region

Laboratory investigations**Report of ultrasonography abdomen- 10-07-18**

Uterus-Bulky in size, 100m X 50mm and appears normal in echo texture.

A cyst measuring 35mm is seen in left ovary with thin internal septation seen within it.

Impression- Mild bulky uterus with hemorrhagic left ovarian cyst.

Totality of symptoms

Mind- Fear - animals, of - snakes, of
Mind- Delusions, imaginations - die -about to-he is
Mind - Sensitive, oversensitive - general - pain, to
Perspiration - Staining the linen - yellow
Female - Tumors - general - cysts - ovaries

Miasmatic evaluation

Psoro- sycotic predominance

Final drug selection with reason

On the basis of totality of symptoms and after consulting material medica [6] *Lachesis* 200, single dose was prescribed.

Follow up

Patient was prescribed placebo for next three months. After three months ultrasonography report showed no abnormality. Her cyst was resolved completely. Her pain was also cured with this similimum. There was no episode of pain in between.

Reportorial totality

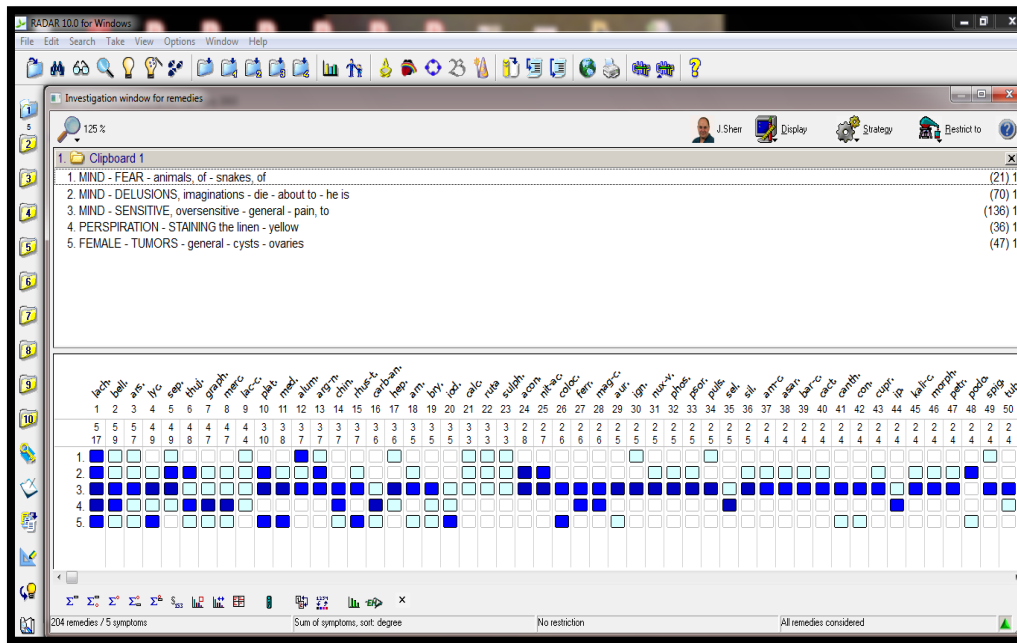


Figure 1: Repertorization done using RADAR software^[5]

DISCUSSION

Large ovarian cysts are difficult to cure. Usually surgery is recommended if not managed with hormonal therapy. But in these types of cases homoeopathic medicines are equally effective with no side effects. Infertility is the most common complication of these types of cysts. Sometime severe pain in abdomen is the chief presenting complaint. Homoeopathic medicines are ray of hope in certain cases which are also cost effective as well.

CONCLUSION

Pain is the presenting symptom in most of the HOCs, which created panick among patients. In this case pain was the presenting symptom. This case was wonderfully recovered with homoeopathic medicine. Cyst resolved completely with the help of homoeopathic medicine.

REFERENCES

1. Abbas AH, Amin MT, Tolba SM, Ali MK. Haemorrhagic ovarian cysts: Clinical and

sonographic correlation with the management options. Middle East fertility society journal. 2016;21:P.41-45
 2. Hahnemann S, Boericke W, Dudgeon R. Organon of Medicine, New Delhi; B. Jain Publishers (P) Ltd.;2011.P.45-47
 3. Close S. The Genius of homoeopathy, lectures and essay on homoeopathic philosophy. New Delhi; B. Jain Publishers (Pvt.) Ltd.; 2008. P.56-60
 4. Dr. Patel RP. Chronic Miasm in Homoeopathy and Their Cure with Classification of their rubrics/symptoms in Kents's Repertory (Repertory of Miasms), 1 ed. Hahnemann House, college road, Kottayam, Kerala; 1996.P.32-33
 5. RADAR [computer program].Version 10.0.028. Archibel.2007.

Cite this article as:
 Aman Deep. A Case of Haemorrhagic Ovarian Cyst Cured with Homoeopathic Similimum. International Journal of Research in AYUSH and Pharmaceutical Sciences, 2020;4(1):385-387.
Source of support: Nil, Conflict of interest: None Declared

***Address for correspondence**
Dr.Aman Deep Ph.D. (Scholar)
 Assistant Professor,
 Department of Community Medicine,
 Dr.MPK Homoeopathic Medical
 college and Research Center, Jaipur.
 Email:
dr.amankaushal90@gmail.com

Disclaimer: IJRAPS is solely owned by Mahadev Publications - A non-profit publications, dedicated to publish quality research, while every effort has been taken to verify the accuracy of the content published in our Journal. IJRAPS cannot accept any responsibility or liability for the articles content which are published. The views expressed in articles by our contributing authors are not necessarily those of IJRAPS editor or editorial board members.